

Management of drug resistant Gram positives- Case Based Discussion

Dr Swati Rajagopal
Consultant- Infectious Diseases
Aster CMI Hospital
Bangalore


Introduction

- The emerging antimicrobial resistance leading to gram-positive infections (GPIs) is one of the major public health threats worldwide. GPIs caused by multidrug resistant bacteria can result in increased morbidity and mortality rates along with escalated treatment cost and hospitalisation stay.
- In India, GPIs, particularly methicillin-resistant *Staphylococcus aureus* (MRSA) prevalence among invasive *S. aureus* isolates, have been reported to increase exponentially from 29% in 2009 to 47% in 2014.

Introduction

- Apart from MRSA, rising prevalence of vancomycin-resistant enterococci (VRE), which ranges from 1 to 9% in India, has raised concerns. Moreover, the overall mortality rate among patients with multidrug resistant GPIs in India is reported to be 10.8% and in ICU settings, the mortality rate is as high as 16%.

The Disheartening Current Status of the 10 x '20 Initiative



10
9
8
7
6
5
4
3
2
1

Bad Bugs
Need Drugs



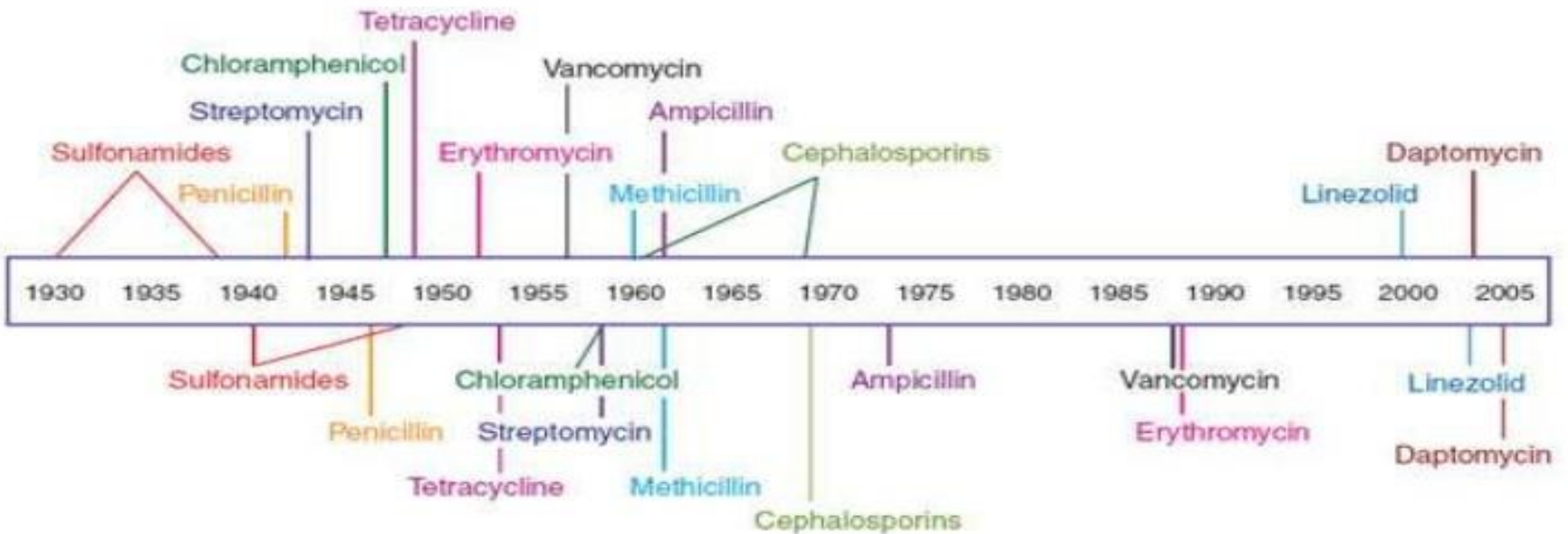
Ten new ANTIBIOTICS by 2020

1 **ceftaroline fosamil:** Forest Laboratories, Inc.
Approved October 29, 2010



Timeline of Antibiotic Resistance

Antibiotic deployment



Antibiotic resistance observed

Modification/Protection of the Target site

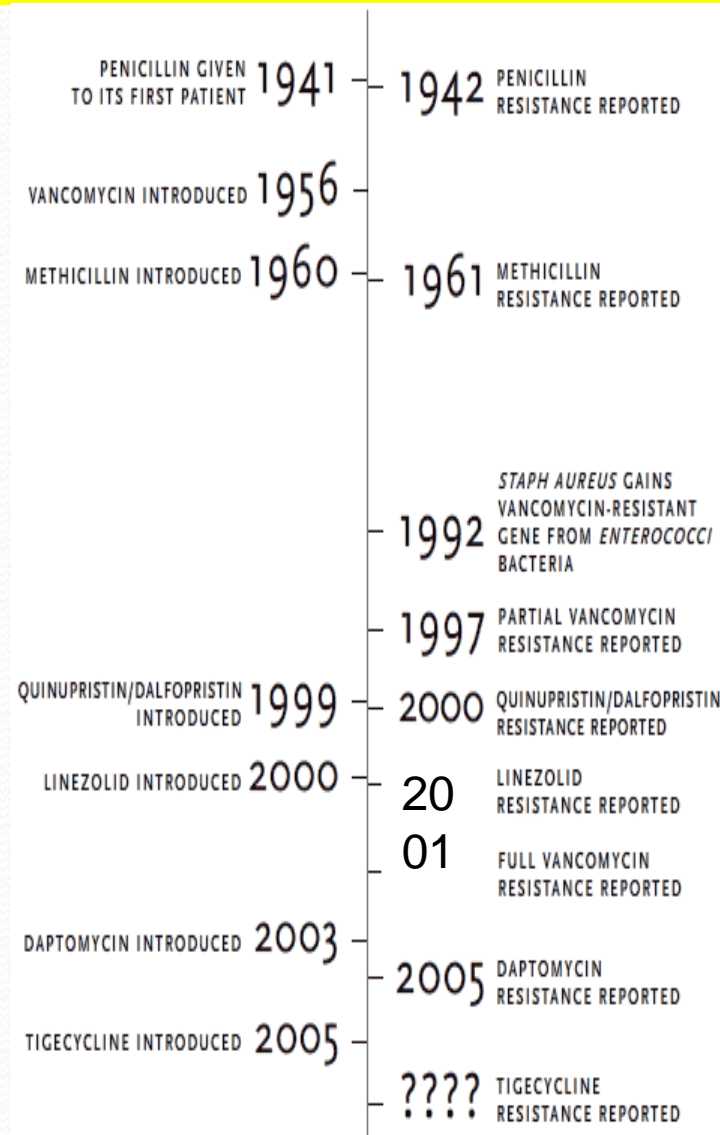
Resistance resulting from altered target sites :

Target sites	Resistant Antibiotics
Ribosomal point mutation	Tetracyclines, Macrolides , Clindamycin
Altered DNA gyrase	Fluoroquinolones
Modified penicillin binding proteins (Strepto.pneumonia)	Penicillins
Mutation in DNA dependant RNA polymerase (M.tuberculosis)	Rifampicin

Major Gram-Positive Pathogens

- Staphylococcus aureus.
- Coagulase Negative Staphylococci
- Enterococci.
- Streptococcus pneumoniae
- Streptococcus spp
- Diptheroids.
- Actinomycetes spp.
- Corynebacterium spp.

Once upon a time, a scientist named Fleming discovered the miracle of antibiotics.....



Case 1

- **A 55-year-old woman was brought to the emergency department after a syncopal episode. Her medical history was significant for type 2 diabetes mellitus, end-stage renal disease requiring maintenance haemodialysis and Charcot arthropathy. Three months prior to the current admission, she was treated for MRSA bacteraemia from an unknown source, with an 8-week course of intravenous daptomycin.**
- **During the index admission, the patient was brought to the emergency room, with syncope. On further evaluation, she was noted to have a temperature of 96.4°F, heart rate of 122 bpm and blood pressure of 96/61 mm Hg.**

Case 1

- **Physical examination was significant for muffled heart sounds and diffuse crackles in bilateral lung fields. She also had local signs of inflammation, including swelling, redness, warmth and tenderness in her right lower extremity, however, she had no signs of inflammation at the site of her arteriovenous (AV) fistula.**
- **Thus, the most likely source of infection was the right lower extremity rather than the AV fistula. She was given intravenous fluids and started on antibiotics. She was then transferred to the intensive care unit, for a higher level of care.**

Investigations

- **Blood tests revealed white cell count of $25.1 \times 10^9/L$ (normal value $3.4-10.4 \times 10^9/L$) and C reactive protein of 279.2 mg/L (normal value $0.2-5 \text{ mg/L}$).**
- **An initial diagnosis of septic shock due to an infective focus in the right foot was made. The patient was started on vancomycin for the MRSA coverage, given the prior history of MRSA bacteraemia. She was adequately fluid resuscitated and started on norepinephrine, however, she continued to be in refractory shock.**
- **A bedside echocardiogram was performed at this time, showing a large pericardial effusion. A detailed transthoracic echocardiogram performed later showed a moderate-sized pericardial effusion with pericardial fibrinous stranding but no evidence of cardiac tamponade**

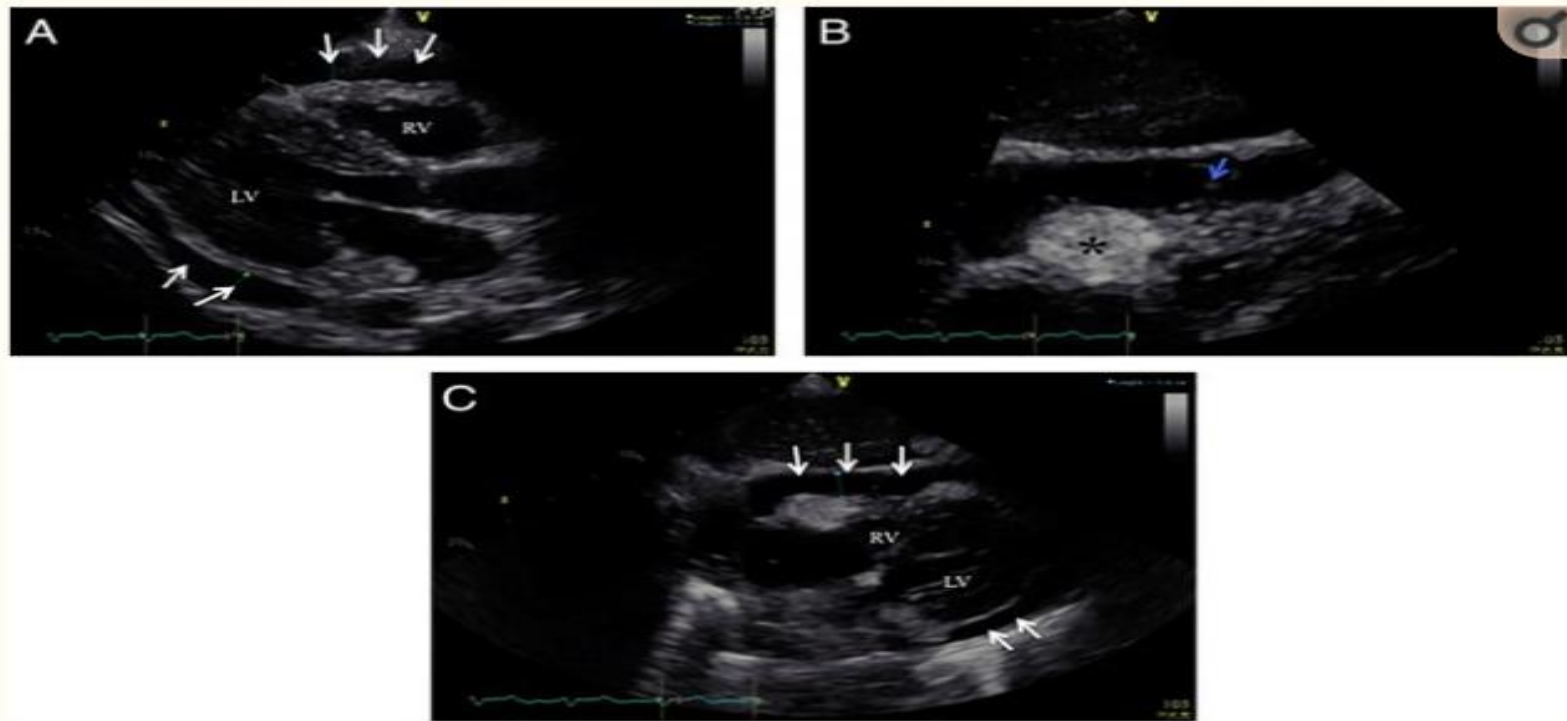


Figure 1

(A) Parasternal long axis image demonstrating circumferential pericardial effusion (white arrows) measuring 1.3 cm during end diastole. Note the absence of collapse of RVOT region. (B) Subcostal view showing moderate-sized circumferential pericardial effusion during systole. (C) Zoomed in image of subcostal view demonstrating anteriorly located moderate-sized pericardial effusion with fibrinous strand (blue arrow). Also note prominent density in the AV groove region, most likely due to epicardial fat (black asterisk). (LV, left ventricle; RV, right ventricle; RVOT, right ventricular outflow tract).

Diagnosics

- **Given the haemodynamic compromise, an emergent pericardiocentesis was performed, which drained purulent fluid. A pigtail catheter was left in place and daily flushing with saline solution was performed. The surgical team was consulted.**
- **No further surgical intervention was recommended due to improving purulent pericardial effusion as seen on serial echocardiograms. The pigtail catheter placed in the pericardial space was removed after 5–7 days without any complications.**
- **Blood and pericardial fluid cultures were found to be positive for MRSA. This led to a search for the primary source of sepsis**

Laboratory Report

Printed Feb 13, 2019 01:03 IST

Printed by: Microlab

BioMérieux Customer:

System #:

Patient Name:

isolate: (Approved)

Patient ID: 700229186

Bench: Others

Card Type: GP Bar Code: 2420846203601906 Testing Instrument: 000018144AE1 (15933)

Card Type: AST-P628 Bar Code: 5380858403225980 Testing Instrument: 000018144AE1 (15933)

Setup Technologist: Microlab(Microlab)

Bionumber: 050402062763271

Organism Quantity: moderate

Selected Organism: Staphylococcus aureus

Susceptibility Information	Card: AST-P628		Lot Number: 5380858403		Expires: Apr 2, 2020 12:00 IST	
	Completed: Feb 5, 2019 17:49 IST		Status: Final		Analysis Time: 8.52 hours	
Antimicrobial	MIC	Interpretation	Antimicrobial	MIC	Interpretation	
Cefoxitin Screen	POS	+	Linezolid	2	S	
Benzylpenicillin	>= 0.5	R	Daptomycin	0.5	S	
Oxacillin	>= 4	R	Teicoplanin	<= 0.5	S	
Gentamicin High Level (synergy)			Vancomycin	1	S	
Gentamicin	>= 16	R	Tetracycline	<= 1	S	
Ciprofloxacin	4	R	Tigecycline	<= 0.12	S	
Levofloxacin	4	R	Nitrofurantoin	<= 16	S	
Inducible Clindamycin Resistance	NEG	-	Rifampicin	<= 0.03	S	
Erythromycin	>= 8	R	Trimethoprim/Sulfamethoxazole	>= 320	R	
Clindamycin	0.25	S				

= Deduced drug *= AES modified **= User modified

AES Findings:	Last Modified: Apr 30, 2018 12:12 IST		Parameter Set: Copy of Global CLSI-based+Natural Resistance(2018)	
	Confidence Level:	Consistent		
Phenotypes flagged for review:	BETA-LACTAMS	MODIFICATION OF PBP (mecA)		

Further hunting for source

- **MRI of the right ankle was obtained given the patient's history of Charcot arthropathy and also due to severe tenderness on palpation of the right ankle during examination. MRI revealed a massively distended synovial fluid complex with possible superimposed infection .**
- **An orthopaedics consult was obtained and a bedside arthroscopy followed by incision and drainage was performed. Ultimately, a right below-knee amputation had to be performed. Wound biopsy and culture from the right fourth metatarsal revealed growth of MRSA and pathology confirmed acute osteomyelitis.**

MRI right foot

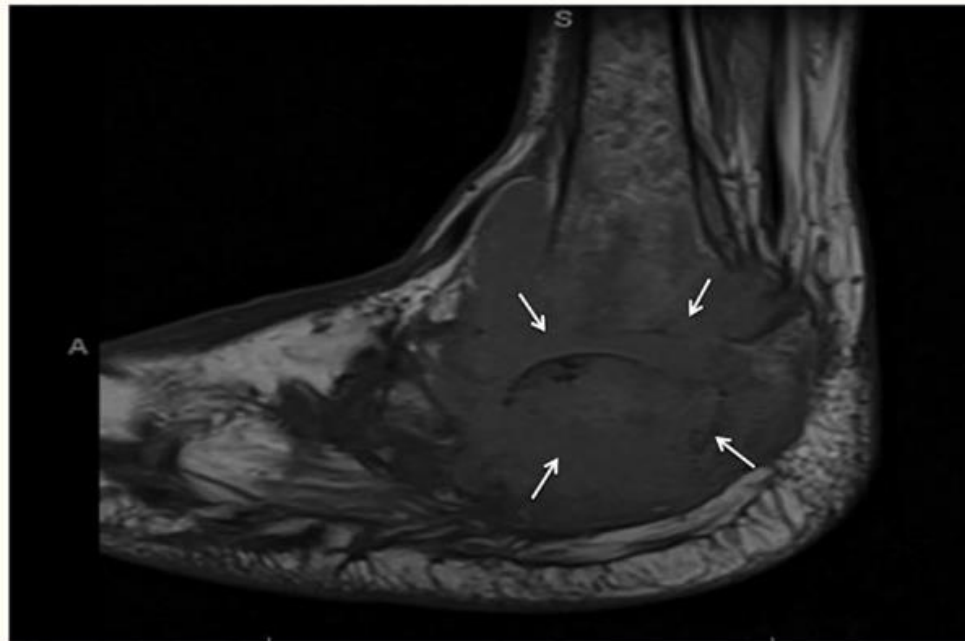


Figure 4

End-stage Charcot arthropathy of the right ankle, hindfoot and midfoot, with an associated massively distended synovial fluid complex (white arrows) and possible superimposed infection.

Outcome and follow-up

- **The patient was discharged in a stable condition from the hospital to a skilled nursing facility. She completed a total of 8 weeks of vancomycin. She was noted to be doing well on follow-up clinic visits.**
- **A transthoracic echocardiogram performed after completion of her antibiotics showed no pericardial effusion.**

Summary

- **55-year-old woman with a history of type 2 diabetes mellitus, Charcot arthropathy and end-stage renal disease, who presented with a syncopal episode after undergoing haemodialysis.**
- **She had a history of methicillin-resistant *Staphylococcus aureus* (MRSA) bacteraemia from an unknown source 3 months earlier, which was treated with an 8-week course of intravenous antibiotics.**
- **At the time of presentation to the emergency room, she was found to be in refractory shock. Bedside echocardiogram was performed, which showed moderate pericardial effusion.**
- **The effusion was later found to be due to MRSA, which was identified in blood and in pericardial fluid cultures.**
- **The patient was successfully treated with intravenous antibiotics for 6 weeks.**
- **Acute osteomyelitis of her right foot was the source of the MRSA, for which a right below-knee amputation was ultimately performed.**

Learning points

- Purulent pericarditis is usually secondary to complication of another infection and thus a high level of suspicion is needed to make a diagnosis.
- Methicillin-resistant *Staphylococcus aureus* purulent pericarditis-related refractory septic shock has a mortality rate of 60%.
- Index of suspicion for staphylococcal pericarditis should be high in an immunosuppressive patient.
- Rapid diagnostic attempts are important as diagnosis can provide source control, which may then result in decreased future complications.
- Completion of antibiotic therapy based on appropriate sensitivity studies is of great importance, and eventually helps in decreasing the mortality.

CASE 2

- A 25-year-old woman with systemic lupus erythematosus and end-stage renal disease underwent mitral valve replacement for severe regurgitation, resulting in hemolytic anemia. Her postoperative course was complicated, requiring 3 returns to the operating room for hemorrhage and cardiac arrest.
- On day 12 after operation, 1 of 2 blood cultures yielded *E. faecium* that was resistant to vancomycin (MIC, ≥ 32 mg/L) and ampicillin (MIC, ≥ 16 mg/L) and susceptible to quinupristin-dalfopristin (MIC, < 0.5 mg/L), linezolid (MIC, < 2 mg/L), daptomycin (MIC, 4 mg/L), rifampin (MIC, 0.016 mg/L) and high-level gentamicin (MIC, < 500 mg/L; actual MIC, 4 mg/L) and coagulase-negative staphylococci, which were considered to be contaminants

Case 2

- **On the day of hospital discharge (day 24 after the operation), another blood sample was obtained for culture. When this culture yielded vancomycin-resistant *E. faecium*(with same susceptibility profile as the previous isolate), linezolid therapy was prescribed by the ID fellow. The treating team apparently wanted to do another set of cultures . But, the registrar of the CTVS team failed to implement.**
- **Notably, she had a femoral dialysis catheter in place that was not removed because of lack of vascular access.**

Case 2

- **Six weeks after the operation, the patient developed chills, nausea, and vomiting, and blood cultures again yielded VRE. Physical examination revealed a new systolic murmur, and transesophageal echocardiography revealed a vegetation (area, 1.2×0.8 cm) on her prosthetic mitral valve. There were no peripheral stigmata of endocarditis.**
- **She was deemed not to be a candidate for surgery. She was initially treated with linezolid (600 mg po q12h for 10 days), which was changed to daptomycin (8 mg/kg iv dose), gentamicin (90 mg iv after each dialysis session), and rifampin (300 mg po q8h).**

Case 2 : Outcome

- **The patient required transfer to the intensive care unit (ICU) twice for management of heart failure. The patient was transferred to another health care unit. After 2 weeks of appropriate antibiotic therapy, she significantly improved .She ultimately received 11 weeks of treatment with daptomycin, gentamicin, and rifampin. There was no relapse, as demonstrated by blood culture.**

Case 3

- **Case of Trigeminal Cystic schwannoma**
- **S/P-extendedendonasal endoscopic approach and excision of left trigeminal cystic schwannoma on 9/8/18**

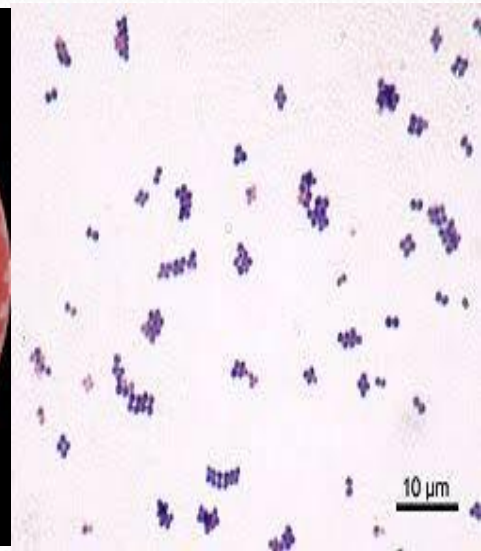
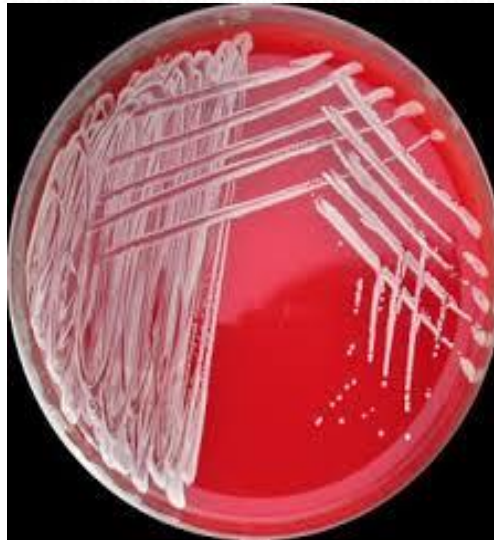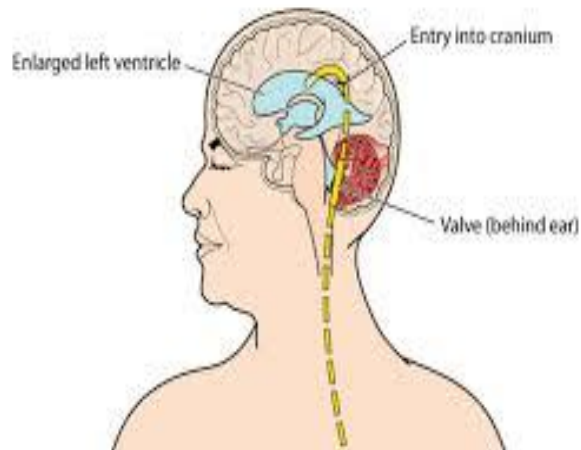
S/P-Left fronto-temporal craniotomy, zygomatic osteotomy subtemporal approach and excision of residual trigeminal schwannoma on 10/8/18

S/P-Rexploration and removal of bone flap with augmentative duroplasty and bone flap in abdomen

Had underwent right VP shunt and left FTP cranioplasty under GA in the same admission

Case 3

Ventriculoperitoneal (VP) Shunt



Case 3

- **Seven days later the patient was readmitted with abdominal pain and sweating. The pain was right-sided, affecting the upper quadrant and was exacerbated by deep inspiration. On admission, the patient appeared ill and was pyrexic (37.9 °C). Peripheral white cell count was 17.5×10^9 /L.**
- **Intra-abdominal sepsis was suspected and a CT scan confirmed the presence of a small subphrenic collection and associated pleural effusion.**

Case 3

- **At the time of surgery, the scalp incision was opened first, and the ventricular tip and a specimen of CSF sent for microscopy and culture. The abdominal wound was then opened and, on removal of the peritoneal catheter, purulent fluid emerged from the abdominal cavity. Specimens of pus and the peritoneal catheter were sent for culture.**

Case 3

- **Initial microscopy and Gram stain of the CSF showed 6/mm³ red blood cells, 6/mm³ white blood cells and scanty Gram-positive cocci. The peritoneal pus contained >3000/mL red blood cells, >3000/mL white blood cells but no organisms were seen. Cultures of CSF, intraperitoneal pus, ventricular catheter tip and peritoneal catheter tip subsequently grew a catalase-positive Gram-positive coccus**

Laboratory Report

Printed Feb 5, 2019 01:03 IST

Printed by: Microlab

bioMérieux Customer:

System #:

Patient Name:

Isolate: 19022013-1 (Approved)

Patient ID: 700216499

Bench: Others

Card Type: GP Bar Code: 2420898103139371 Testing Instrument: 000018144AE1 (15933)

Card Type: AST-P628 Bar Code: 5380858403006132 Testing Instrument: 000018144AE1 (15933)

Setup Technologist: Microlab(Microlab)

Bionumber: 010026112670231

Organism Quantity:

Selected Organism: Staphylococcus warneri

Susceptibility Information	Card: AST-P628		Lot Number: 5380858403		Expires: Apr 2, 2020 12:00 IST	
	Completed: Jan 29, 2019 01:43 IST		Status: Final		Analysis Time: 17.98 hours	
Antimicrobial	MIC	Interpretation	Antimicrobial	MIC	Interpretation	
Cefoxitin Screen	POS	+	Linezolid	2	S	
Benzylpenicillin	>= 0.5	R	Daptomycin	2		
Oxacillin	>= 4	R	Teicoplanin	<= 0.5	S	
Gentamicin High Level (synergy)			Vancomycin	1	S	
Gentamicin	4	S	Tetracycline	<= 1	S	
Ciprofloxacin	<= 0.5	S	Tigecycline	<= 0.12	S	
Levofloxacin	<= 0.12	S	Nitrofurantoin	<= 16	S	
Inducible Clindamycin Resistance	NEG	-	Rifampicin	<= 0.03	S	
Erythromycin	<= 0.25	S	Trimethoprim/Sulfamethoxazole	<= 10	S	
Clindamycin	>= 4	R				

+ = Deduced drug * = AES modified ** = User modified

AES Findings:	Last Modified: Apr 30, 2018 12:12 IST		Parameter Set: Copy of Global CLSI-based+Natural Resistance(2018)
	Confidence Level:	Inconsistent	

Outcome

- **Postoperatively, the patient made a good recovery and intravenous vancomycin with rifampicin was continued for 1 week.**
- **A further 1 week of oral ciprofloxacin and rifampicin was prescribed and the patient was discharged well.**

Learning points

- **CoNS are among the commonest causes of VP shunt infections . It is the ability of these organisms to adhere to indwelling medical devices and form biofilms that allows them to colonize and persist on VP shunts.**
- **CoNS are usually low virulence pathogens and the VP shunt infections they cause are mostly indolent and subacute in presentation. In contrast, *S. aureus* shunt infections frequently manifest a systemic inflammatory response, signs of meningism and involve the shunt and surrounding tissues.**
- **The case described suggests that this strain of *S. warneri* was able to adhere to shunt material and also cause an acute infection similar in clinical picture to *S. aureus* infection.**

Learning points

- ***S. warneri* is usually susceptible to a wide range of antimicrobials, although treatment of CoNS VP shunt infections usually requires shunt removal in addition to antibiotics, as was necessary in this case, to achieve complete clearance of the infecting organism.**
- **Isolation of *S. warneri* should not be disregarded as a contaminant when recovered from a normally sterile body site and should prompt a rapid clinical evaluation by attending clinicians.**
- **Infections of VP shunts by *CONS* can be added to the growing list of site-specific infections caused by this emerging opportunistic pathogen.**

VP shunt infections

- The eradication of infection in patients with colonized shunts has always been a great challenge to the treating surgeon. Various methods have been tried with variable success. Meticulous asepsis preoperatively and intraoperatively is essential in preventing colonization.
- Infections following VP shunt procedure are secondary to catheter blockage complicating the results of surgery and are associated with high morbidity and mortality rates.
- Colonized shunts do not function well mechanically.

VP shunt infections

- Majority of infections occur within one to two months of surgery. The organisms may be isolated solely from the shunt tube, indicating an early colonization. There was no spread of infection to the CSF or to the blood stream.
- Although positive CSF culture might be expected to be the final confirmation of the presence or absence of infection in a shunt *in situ*, cultures may be negative even when the shunt device harbours infection. In such circumstances it could be an indolent infection with colonization of shunt and a sterile CSF.

CONS

- Coagulase negative *Staphylococcus* was the most frequent isolate encountered in our series. In gram positive shunt infections, majority of the organisms are commensals of the skin, a result of direct wound contamination during surgery.
- Although gram negative bacterial colonization of the skin is not common, they could probably be introduced during surgery. Another probable mechanism is 'retrograde' infection, in which an asymptomatic perforation of the bowel leads to distal contamination of the VP shunt catheter and retrograde progression of infection.
- The sources of infection in colonized shunts showed that in majority of cases the causative organism was present at the operative site prior to and during surgery.

Case 4

- **A 17-year-old boy presented to the casualty of our institute with complaints of high fever for 3 days along with headache, vomiting, and altered mental status of 1 day duration.**
- **There was no history of cough, ear discharge, photophobia, and convulsion. He had no previous history of hospital admission or similar illness in the past.**
- **On examination, the patient was febrile, pale and had tachypnea (respiratory rate 24/min). Examination of the central nervous system revealed decreased level of consciousness (Glasgow coma score [GCS] of 6, E1 V1 M4), signs of meningeal irritation (neck rigidity, positive Kerning's and Brudzinski's sign), bilateral extensor planter response and normal muscle tone and deep tendon reflexes. Both pupils were equal in size and reacting to light. Skin rash and hepatosplenomegaly were absent.**

Case 4

- He was clinically diagnosed as community acquired (CA)-ABM. Cerebrospinal fluid (CSF) sample was sent for cell count, biochemical analysis, and culture. CSF was turbid in appearance and had pleocytosis (>240 leucocytes/ μ l, of which 80% were neutrophils). Biochemical analysis of CSF showed decreased glucose (20 mg/dl) and elevated protein (136 mg/dl) level.
- Microscopy of the gram stained smear of both uncentrifuged and centrifuged CSF showed Gram-positive lanceolate shaped cocci, mostly in pairs, without any capsule along with numerous pus cells

Case 4

- **Antibiotic susceptibility testing was carried out as per Clinical Laboratory Standards Institute Guidelines . The isolate was resistant to penicillin and showed sensitivity to ceftriaxone, erythromycin, cotrimoxazole, chloramphenicol, tetracycline, ciprofloxacin, vancomycin, and rifampicin.**
- **A blood culture done on 2nd day of hospital admission was sterile. The child was treated with intravenous ceftriaxone and supportive therapy. Fever decreased with improvement of GCS, and he was discharged after 10 days. It was identified as *S. pneumoniae***

Laboratory Report

Printed Jan 10, 2019 01:03 IST
 Printed by: Microlab

Customer: Merieux
 Item #:

Patient Name:
 Plate: 18342530-1 (Approved)

Patient ID: 700224894
 Bench: Others

Card Type: GP Bar Code: 2420846203603179 Testing Instrument: 000018144AE1 (15933)
 Card Type: AST-ST03 Bar Code: 5420785203517079 Testing Instrument: 000018144AE1 (15933)
 Setup Technologist: Microlab(Microlab)

Lot Number: 161133364301130
 Organism Quantity:

Selected Organism: Streptococcus pneumoniae

Susceptibility Information	Card: AST-ST03		Lot Number: 5420785203		Expires: Jan 20, 2020 12:00 IST	
	Completed: Jan 3, 2019 02:09 IST		Status: Final		Analysis Time: 14.58 hours	
Antimicrobial	MIC	Interpretation	Antimicrobial	MIC	Interpretation	
Benzylpenicillin			Levofloxacin	1	S	
Pneumonia	>= 8	R	Moxifloxacin	0.12	S	
Oral	>= 8	R	Inducible Clindamycin Resistance			
Meningitis	>= 8	R	Erythromycin	>= 8	R	
Other	>= 8	R	Clindamycin	>= 1	R	
Ampicillin			Linezolid	<= 2	S	
Cefotaxime			Teicoplanin			
Meningitis	<= 0.12	S	Vancomycin	>= 8		
Other	<= 0.12	S	Tetracycline	2	I	
Ceftriaxone			Tigecycline	<= 0.06	S	
Meningitis	<= 0.12	S	Chloramphenicol	2	S	
Other	<= 0.12	S	Rifampicin	<= 0.06	S	
Gentamicin			Trimethoprim/Sulfamethoxazole	40	I	

+ = Deduced drug * = AES modified ** = User modified

AES Findings:	Last Modified: Apr 30, 2018 12:12 IST	Parameter Set: Copy of Global CLSI-based+Natural Resistance(2018)
Confidence Level:	Inconsistent	

Action	Name (User ID)	Date/Time	Comment
Reviewed by:	(Microlab)	Jan 3, 2019 08:42 IST	

Learning points

- **Pneumococcal meningitis accounts for 34.3% to 43.5% of Invasive Pneumococcal disease in India . With the increasing use of Haemophilus influenzae type b conjugate vaccine S. pneumoniae has emerged as the most common agent of CA-AMB in children as well as in adults in several parts of the world .**
- **Meningeal seeding of S. pneumoniae during bacteremia is usually the most common mode of meningeal involvement. Less frequently, a breach in dura associated with head injury with a skull fracture and neurosurgery can also lead to spread of S. pneumoniae from infected paranasal sinuses, mastoid, and middle ear .**

Learning points

- Whereas, Chawla et al. detected 14% strains of *S. pneumoniae* had reduced penicillin susceptibility . Ceftriaxone or cefotaxime alone or in combination with vancomycin have been found to useful in treating these infections . Treatment with an intravenous Ceftriaxone resulted in rapid clinical improvement without any neurological sequelae.
- Good therapeutic outcome of *S. pneumoniae* meningitis depends on early diagnosis and initiation of appropriate antibiotic. With respect to the emergence of penicillin resistance in *S. pneumoniae*, antibiogram has a critical role in guiding antibiotic therapy in such cases.
- Vaccination critical

Treatment-options

Table 1: Gram positive organisms and recommended antimicrobial agents.

Organism	Recommended drugs
MSSA	Cefazolin, Cloxacillin
MRSA	Vancomycin, Daptomycin, Teicoplanin, Linezolid, Ceftaroline, Tigecycline
VISA, hVISA, VRSA	Combination of high-dose daptomycin with another antibiotic including gentamicin, rifampicin, linezolid, trimethoprim-sulfamethoxazole (TMP-SMX), or a β -lactam
VRE	Linezolid, High-dose ampicillin, daptomycin; nitrofurantoin, Fosfomycin (UTI); doxycycline, chloramphenicol, gentamicin, streptomycin (combination therapy)
DRSP	Respiratory fluoroquinolones (moxifloxacin, Gemifloxacin, or levofloxacin), or a beta-lactam alone or in combination with a beta-lactamase inhibitor (high dose amoxicillin or amoxicillin-clavulanate) along with doxycycline

New drugs in the pipeline

Table 3: Some new drugs recently approved and in pipeline for treatment of gram-positive infections.

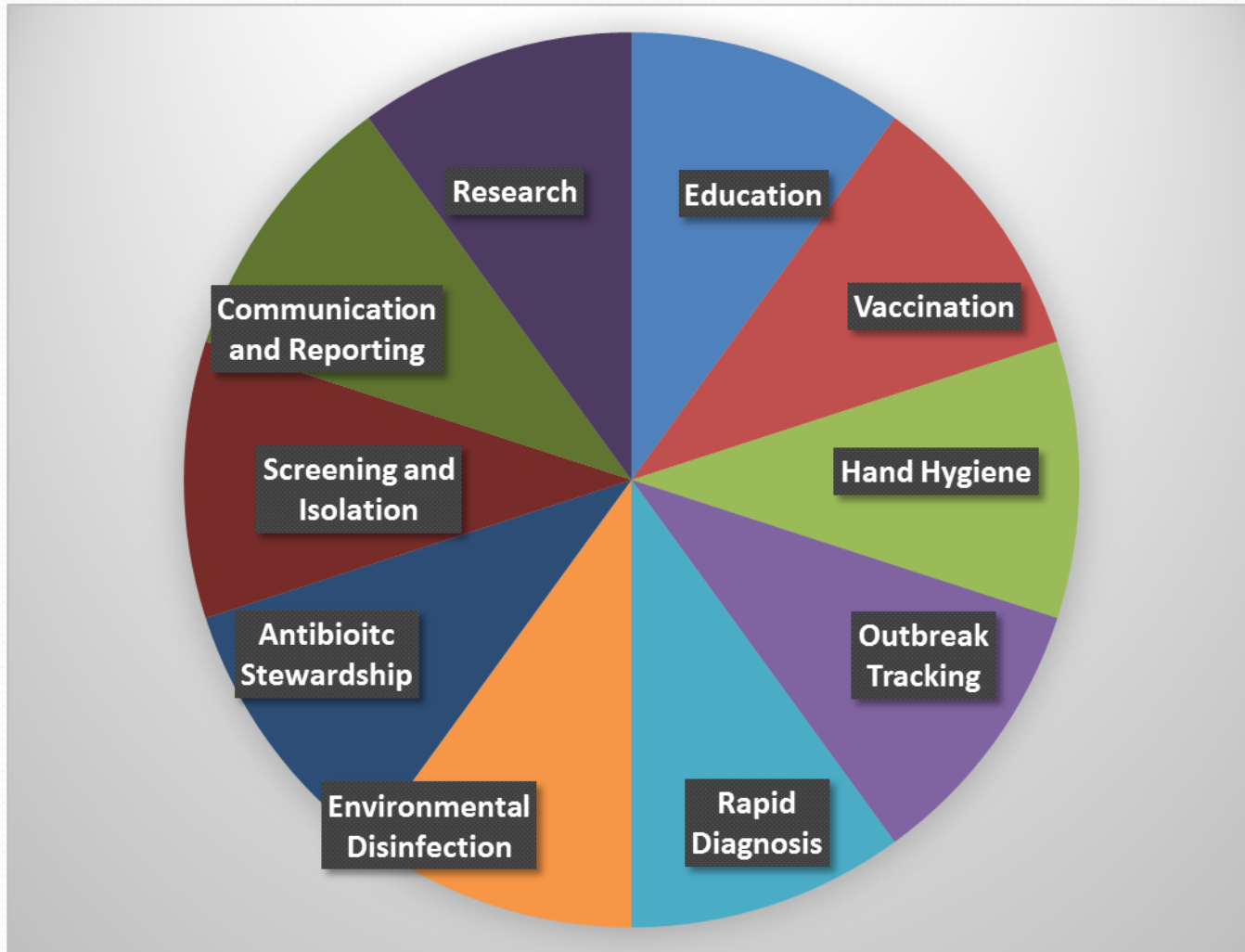Name of the drug	Class	Mechanism of action	Important GP organisms covered*	Dose and Route [†]	Phase of testing [‡]	Serious Adverse effects** [‡]
Delafloxacin			MRSA, MSSA, <i>St. pyogenes</i> , <i>E. faecalis</i>	300 mg IV/ 450 mg oral	USFDA approved in June 2017	Tendinitis and tendon rupture, peripheral neuropathy, Central nervous system effects
Nemonoxacin	Fluoro-quinolone	Inhibit DNA gyrase and Topoisomerase IV	MRSA, VRSA	250-750 mg, oral, IV	Phase III	None reported
Levonadifloxacin			MRSA, VRSA	1000 mg oral, 800 mg IV	Phase III	None reported
Alalevonadifloxacin			MRSA, VRSA	1000 mg oral	Phase III	None reported
Solithromycin	Fluoro-ketolide	Inhibits protein synthesis by binding to 50s ribosome subunit and blocking peptide chain elongation	<i>S. aureus</i> , <i>St. pneumoniae</i>	800 mg oral	Phase III	Possible hepatotoxicity
Omadacycline	Tetracycline	Inhibits protein synthesis by binding to 30s ribosome subunit and blocking binding of aminoacid-tRNA with mRNA	<i>S. aureus</i> (MSSA), <i>St. pneumoniae</i>	100-200 mg IV; 300-450 mg oral	USFDA approved in October 2018	Similar to other tetracyclines
Eravacycline			<i>E. faecalis</i> , <i>E. faecium</i> , <i>S. Aureus</i> , <i>St. anginosus</i> group	1 mg/kg IV infusion	USFDA approved in August 2018	Similar to other tetracyclines
Tedizolid	Oxazolidinone	Inhibits protein synthesis by binding to the 50S ribosome subunit	MRSA, MSSA, <i>St. pyogenes</i> , <i>St. agalactiae</i> , <i>S. pneumoniae</i> , <i>E. faecalis</i>	200 mg oral or IV infusion	USFDA approved in June 2014	Similar to linezolid

New Drugs in the pipe line

Lanopepden (GSK'322)	Peptidyl deformylase inhibitor	Inhibits bacterial protein synthesis	<i>St. pneumoniae, St. pyogenes, S. aureus</i>	1500 mg oral	Phase II	None reported
AFN-1252	FabI (enoyl ACP reductase) inhibitor	Interferes with essential bacterial fatty acid biosynthetic pathway	<i>S. aureus, S. epidermidis, other staphylococci</i>	200 mg oral	Phase II	None reported

Control

(How to Prevent Resistance and Lower Cost)



How Does Alere Help Manage This Crisis?

Does the patient need antibiotics?

Flu

RSV

Strep A



Which antibiotics are most appropriate?

Strep pneumo

Legionella

Strep A



Do they have an antibiotic resistant bacteria?

MRSA



Do they have an antibiotic-associated disease?

C. difficile

Challenges

- **Another challenge is the spectrum of adverse effects related to the safety and tolerability profile of the currently available drugs used against GPIs which further makes the management and treatment of these multidrug resistant organisms a complex task.**
- **Judicious prescription of antimicrobial agents, implementation of antibiotic stewardship programmes, and antibiotic policies in hospitals are essential to reduce the problem of drug-resistant infections in India.**



recommends:

Combating Antimicrobial Resistance:
Policy Recommendations to Save Lives

CID 52 (Suppl 5):S397, 2011
Infectious Diseases Society of America (IDSA)

- 1. Adoption of Economic Incentives and Collaborative Mechanisms to Address the Market Failure of Antibiotics**
- 2. New Regulatory Approaches to Facilitate Antimicrobial Development & Approval**
- 3. Greater Coordination of Relevant Federal Agencies' Efforts**
- 4. Enhancement of Antimicrobial Resistance Surveillance Systems**
- 5. Strengthening Activities to Prevent and Control Antimicrobial Resistance**
- 6. Significant Investments in Antimicrobial-Focused Research**
- 7. Greater Investment in Rapid Diagnostics R&D and Integration into Clinical Practice**
- 8. Eliminating Non-Judicious Antibiotic Use in Animals, Plants & Marine Environments**

Concluding remarks

- **Gram positive bacteria are responsible for causing significant infections in the healthcare and ICU setting. The development of drug resistance in these organisms is a serious problem, leading to difficult-to-treat infections by MRSA, VISA, VRSA, VRE, and other multidrug resistant organisms.**
- **The prevalence of resistance is bound to increase with increased irrational use of antibiotics. Steps such as restricting usage of antibiotics and antibiotic stewardship programmes need to be enforced strictly. The most important step, however, is the increased push towards development of newer antibiotics against the gram-positive bacteria with novel targets.**